



ELSEVIER

Contents lists available at ScienceDirect

The Foot

journal homepage: www.elsevier.com/locate/foot

Algorithm for the management of antibiotic prophylaxis in onychocryptosis surgery

Antonio Córdoba-Fernández*, Gloria Ruiz-Garrido, Ángela Canca-Cabrera

School of Health Sciences, Department of Podiatry, Seville University, C/Avicena, s/n, Seville, Seville 41009, Spain

ARTICLE INFO

Article history:

Received 4 March 2010

Received in revised form

16 September 2010

Accepted 17 September 2010

Keywords:

Antibiotic

Prophylaxis

Onychocryptosis

Surgery

ABSTRACT

Background: Antibiotic prophylaxis in nail surgery is not clearly established, and there is scant scientific evidence regarding the need for its use in preventing surgical site infection, hematogenous total joint infection, and infective endocarditis.

Objectives: To propose an algorithm based on the evidence for the management of antibiotic prophylaxis in onychocryptosis surgery.

Methods: A literature review was performed in Medline, Pubmed, Cochrane database and Scopus and recent prospective studies were examined. The most-current authoritative guidelines together with new classification system of the pathology have been taken into account.

Results: In non-risk patients with onychocryptosis stage II or III phenol technique can be used without the need for antibiotics. In stages IV and V, specific antibiotic treatment should be administered before surgery together with partial ablation of nail until the infection is resolved and the process reverts to stage II or III. In the case of long-developing onychocryptosis, osteomyelitis should be ruled out, and specific antibiotic treatment besides the preoperative dose should be administered. In high-risk cardiac patients with infective onychocryptosis, the need for prophylaxis for bacterial endocarditis should be considered.

Conclusion: Current evidence does not support the use of preoperative antibiotic prophylaxis in onychocryptosis surgery except in special patients with infective onychocryptosis.

Published by Elsevier Ltd.

1. Introduction

Onychopathies, and in particular onychocryptosis, are frequent reasons for consultation in the podiatric clinic day by day. The patient usually seeks treatment when the pathology is accompanied by considerable localized infection, drainage, erythema, and pain. However, the use of antibiotics associated to the nail surgical treatment is not clearly established, and the scientific evidence for or against its use associated to surgical ingrown-toenails treatment, aimed of improving the clinical course of the pathology, is poor. Currently, the use of antibiotics as an essential component of treatment is controversial. Some authors hold that the use of oral antibiotics prior to surgical procedures associated to matricectomy reduces the risk of developing an infection [1,2]. On the other hand, the role of antibiotic prophylaxis in dermatologic surgery remains equally controversial [3]. The adverse effects of prophylactic antibiotic use include increased cost, drug reactions, the development of antibiotic resistance, and medication interaction. Some authors support that if partial nail avulsion is performed in the earlier stages

of the onychocryptosis, the localized infection can be resolved spontaneously without the need for antibiotics [4]. Some clinical trials carried out on patients with ingrown nails in the presence of infection question the use even of perioperative antibioticotherapy [5,6]. The scarcity of data and the insufficiency of clinical trials mean that today there is no consensus on the use of antibiotics in nail surgery. Because of this controversy, the present study is aimed at establishing a clinico-therapeutic algorithm based on the existing evidence, and on accepted guidelines in accord with the authority of the main scientific societies specializing in the topic (the British Society for Dermatological Surgery in agreement with the British Society for Antimicrobial Chemotherapy and the American Heart Association, American Dental Association with the American Academy of Orthopedic Surgeons.

2. Surgical-site infection in nail surgery

Most bacteria resident in the skin are found at a depth of 0.3 mm. The nail folds, because of their morphology, provide an excellent habitat for these bacteria. Rayan and Flournoy found that *S. epidermidis* is the main microorganism resident on the fingernails, this area of skin being where the highest number of these microorganisms are located, in spite of adequate preoperative hand

* Corresponding author. Tel.: +34 954486539; fax: +34 954482171.

E-mail address: acordoba@us.es (A. Córdoba-Fernández).

scrubbing, the fingernails were heavily contaminated [7]. Edwin et al. found that, after the toenail furrows are brushed, the bacterial flora decreases by some 55%; the authors found that surgical brushing was effective only after partial ablation of the nail plate, and that it reduced the number of colonies by only 22%. They concluded that the presence of microorganisms justifies the use of antibiotic prophylaxis. The same study found that *S. epidermidis* – the main pathogen implicated in systemic infections – was the most frequently isolated pathogen of the periungual flora [8]. Such studies maintain that, even in the absence of infection, the practice of nail surgery should be considered contaminating surgery, and when it is associated to infection, dirty surgery. Any current prospective studies carried out in patients with extirpation of cutaneous lesions in the absence of antibiotic prophylaxis have found an unacceptable rate of postoperative infections (more than 5%) [9]. A recent study carried out on 857 skin surgery procedures found a postoperative infection rate of 8.6%, with a higher infection rate in patients with diabetes, with diagnosis of skin cancer, and in lesions located in thighs, legs, or feet. The study found that the highest percentage of infections was in legs and feet, reaching some 15% of the total [10]. However, most guides of clinical practice in dermatology advise against antibiotic prophylaxis in the absence of infection (clean surgery or clean contaminated skin), regardless of cardiac history. In contaminated, dirty and/or infected classes of wounds the risk of wound infection is higher (>25%), elective skin surgery should be postponed if possible until the wound infection is treated with therapeutic antibiotics [3,11].

3. Infection in onychocryptosis: considerations

Systems of classification and algorithms of treatment depending on the severity of the signs and symptoms accompanying an ingrown nail (localized infection, drainage, erythema, and pain) have been proposed [12]. Some authors have proposed classification systems based not only on the clinical severity but also on the depth of the nail folds [13]. Recently, Kline proposed a new classification and algorithm of treatment based not only on the signs and symptoms but also on the existence of earlier episodes of the pathology, the presence of onycholysis, and long-developed infection [14]. In order to select in each case the surgical procedure that is simplest and gives the best aesthetic results, the author emphasizes on the one hand the need to establish a proper evaluation of the degree and period of development of the infection accompanying the process, and on the other to determine the existence of a prior history of infection in the border or borders affected. Five stages are established:

Stage I: Local irritation of the nail fold without gross infection or granulation tissue, with or without prior history of onychocryptosis. Treatment is based on debridement of the affected nail border and extirpation of the spicule without the need for local anesthesia.

Stage II: Infection of the nail border with pus and/or granulation tissue, without prior history of onychocryptosis. The treatment indicated in such case is extirpation of the granulation tissue associated to the Suppan I technique or chemical matricectomy with phenol.

Stage III: Infection of the nail border, with a history of more than one episode of onychocryptosis in the affected nail border. This stage differs from the former only by the existence or not of a prior history of the pathology. The treatment proposed in this phase is a chemical or laser matricectomy, or use of the Winograd technique.

Stage IV: Infective onychocryptosis with partial onycholysis of one of the borders.

Stage V: Infective onychocryptosis of both borders. The onycholysis of the nail plate can be total or partial of both nail borders.

The author rules out, in cases of infective onychocryptosis, a chemical matricectomy, and advises the partial ablation (unilateral or bilateral) or even a complete avulsion of the nail plate in severe cases, and specific treatment of the infection. Some authors emphasize the advisability in cases of chronic onychocryptosis (of six months or more) of ruling out the existence of associated osteomyelitis. The presence of periostitis, osteitis, or osteomyelitis should be ruled out with a radiograph or MRI, and the result – if it is not very clear – possibly confirmed with a gammagraph. In severe cases of chronic onychocryptosis it might be necessary to carry out, prior to the definitive surgical treatment, a partial ablation or complete nail plate avulsion with irrigation, drainage and resection of involved bone, which should be cultured. The authors recommend not carrying out the definitive surgical procedure (resection of hypertrophic unguis) until the resolution of the infectious process [14–17].

4. Considerations for administration of antibiotic prophylaxis in nail surgery

The morbidity of local surgical infection depends largely on the site of infection and on the characteristics of the patient. These are determinant factors when proposing the need for antibiotic prophylaxis for the surgery. Local surgical infection is associated to various pathologies, depending on the location and the clinical context. The use of antibiotics is justified on one hand by an increased potential risk of infection associated to the surgical site and, on the other, to the increase in morbidity that this can involve, including bad aesthetic results deriving from it. Although there is insufficient evidence available on a reduction in the range of infections, some authors consider the use of antibiotic prophylaxis reasonable for minor excisions. There is some evidence of a 50% reduction in the risk of infection when perioperative antibiotic prophylaxis is used together with clean surgery [9], however, the disadvantages of antibiotic prophylaxis should not be overlooked. These include increased cost, adverse drug reactions, antibiotic resistance, and medication interactions.

Another controversial aspect comes from analyzing the evidence of the increase in infection rate related with the most widespread surgical procedure in the treatment of onychocryptosis – segmental phenolization. The main disadvantage of this technique is associated to the increased period of cicatrization, generally accompanied by a considerable inflammatory reaction and prolonged serous drainage [17]. The procedure is often followed by an abscess at eponychial level and – occasionally – necrosis from acid coagulation generates a slough, impeding drainage and facilitating infection. Existing evidence has demonstrated that the phenol technique significantly increases the infection rates compared with other techniques such as *wedge excision* [17,18]. However, it can be used in the presence of concomitant infection, as the phenol has an antiseptic effect. There is little evidence of the effectiveness of antibiotics associated to the use of phenol. Only one study, by Reyzelman et al., has been carried out to determine whether antibiotic therapy is effective in onychocryptosis patients subjected to segmental phenolization [6]. In that study, 154 patients were distributed randomly in three groups. The patients of the first group were orally administered 500 mg of cephalexin every 6 h for one week following surgery; the second group were administered the same dose for a week and then operated; the third group were phenolized without antibiotic treatment. The authors conclude that there was no significant difference between the groups, and that therefore the use of antibiotics as therapy associated to surgical treatment of onychocryptosis does not play a determinant role in reducing the time of cicatrization.

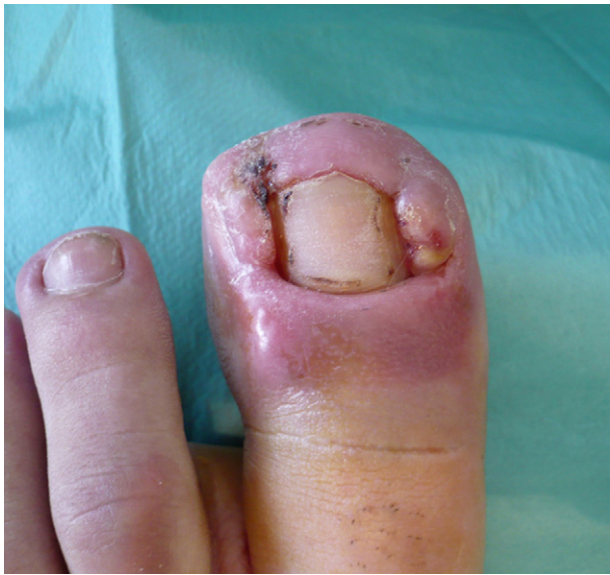

Fig. 1. Clinical appearance showing chronic onychocryptosis in stage V. The cellulitis of both nail borders can be observed.

Although postoperative wound infection is a potential complication of dermal surgery, Hirschmann stated that the occurrence in dermatologic surgery is too infrequent to justify the use of systemic antibiotic prophylaxis, except in special circumstances [19]. These special cases include patients with numerous staphylococcal skin infections or recurrent cellulitis. Some podiatric references have shown the need for appropriate treatment of infection in cases of developed chronic onychocryptosis accompanied by cellulitis and radiological signs of periostitis or osteomyelitis (Figs. 1 and 2) [15,20]. The authors emphasize the need for a proper radiological monitoring of possible osseous manifestations if the progress of the infection is adverse after an empirical antibiotic treatment, and recommend the carrying out of drainage, bone resection, and culture and antibiogram, followed by the administration of specific antibiotics until the infectious process remits, maintaining them for at least two weeks [14–16,20].

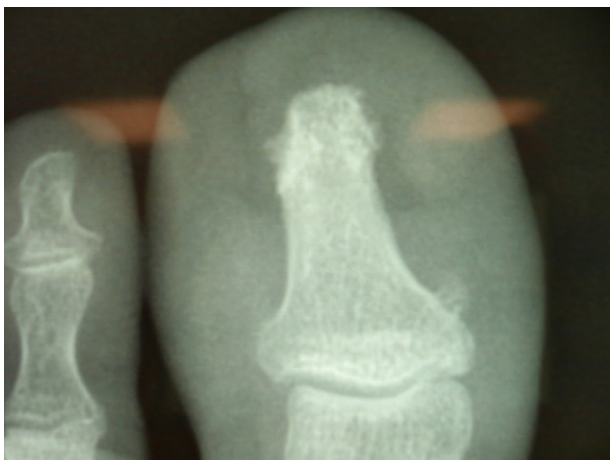


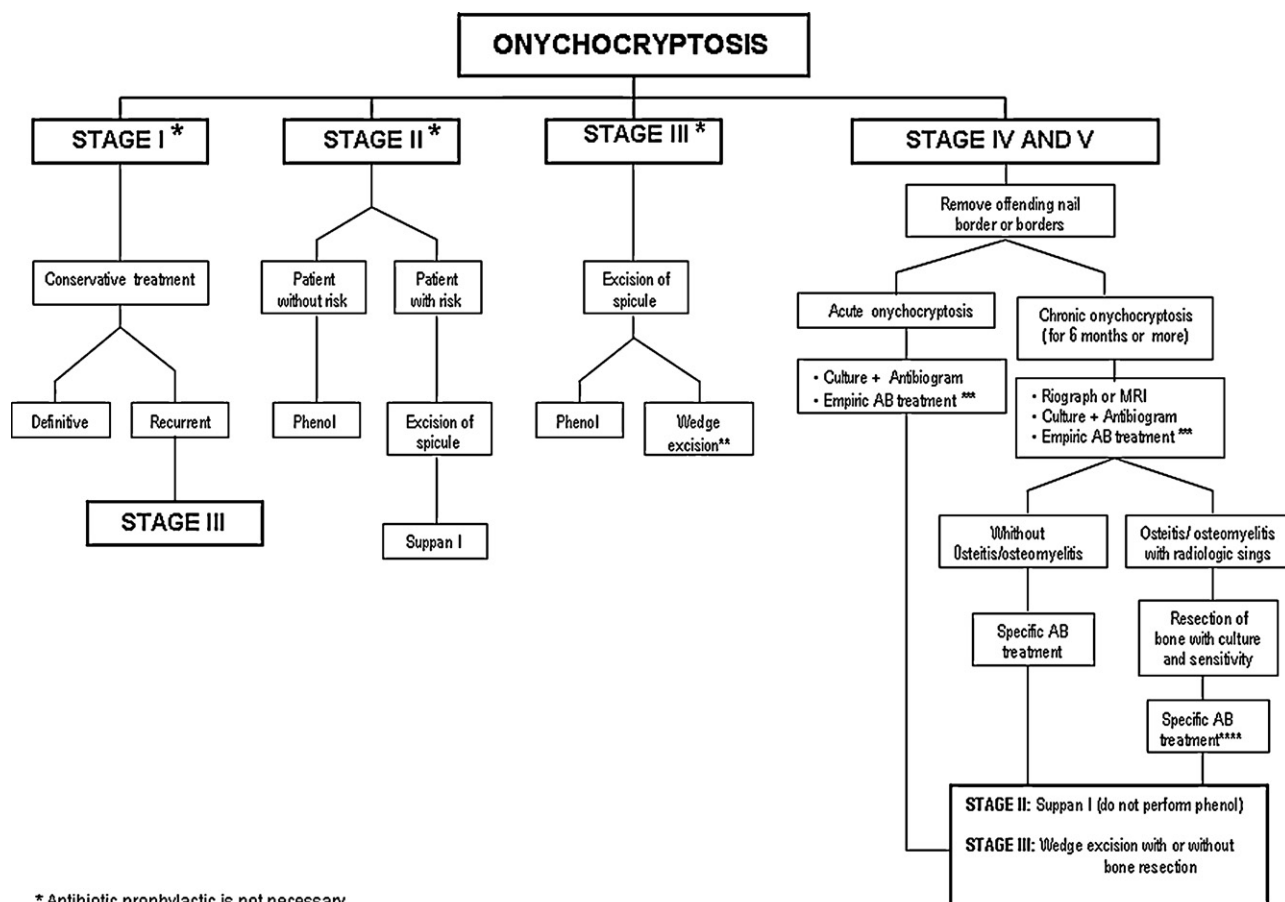
Fig. 2. Anteroposterior radiograph showing lysis of the distal aspect of distal phalanx.

5. Prevention of infective endocarditis and hematogenous total joint infection in onychocryptosis surgery

The risk of local spreading of the infection is also associated to the potential risk of articular infection by hematogenous dissemination, or even the risk of bacterial endocarditis. Most of the clinical trials carried out coincide in indicating a low risk (around 2%) of bacteremia secondary to procedures of dermatological surgery on non-infected healthy skin [21–23]. Bobrow et al. reported that the incision and drainage of localized cutaneous abscesses in afebrile adults was unlikely to result in a transient bacteriemia [24]. A study carried out by Trepal et al. found that the risk of intraoperative bacteriemia or septicemia during foot surgery is negligible [25]. On the other hand, the literature suggests that antibiotic use is probably not warranted for prevention of surgical wound infection, endocarditis, and late prosthetic joint infections [26]. The incidence of bacteriemia in outpatient dermatologic surgery is 3%. According to the AHA, there is a higher risk of endocarditis if the probability of bacteriemia is greater than 10%. The evidence is less clear regarding the need for antibiotic prophylaxis in prolonged Mohs procedures, delayed repairs, grafts, electrocution or ablative laser techniques, and procedures that breach a mucosal surface. Many procedures of nail surgery are associated to the carrying out of incision and drainage, curettage, excision, and in some cases the use of electrocution or ablative laser techniques [27–29], nevertheless the use of systemic antibiotics in laser resurfacing is not clearly indicated [26]. Currently, most guides of dermatological surgery adapted from the Authoritative guidelines recommend prophylaxis with antibiotics in patients with high cardiac risk or potential increased risk of prosthetic joint infection who receive surgery in the presence of local infection (dirty surgery) [30]. The existing guides of clinical practice indicate that when surgery takes place on infected skin and in cardiopathic patients at risk of endocarditis, the infection should be treated aggressively with antibiotics active against *S. aureus* and B-hemolytic streptococci. These microorganisms are those that cause most infections of the skin and soft parts in the community [31]. Current guides recommend prior treatment of infection at the surgery site to reduce the risk of hematogenous bacterial dissemination. Such treatment should include suitable doses of antibiotics that cover the probable pathogens in the zone. The protocols also recommend that, in a community with increased risk for *methicillin-resistant S. aureus* (MRSA), infective endocarditis/hematogenous total joint infection prophylaxis be considered. Where possible, it would be reasonable to perform a culture to determine the existence of especially resistant pathogens (MRSA) [31].

6. Recommendations for administration of antibiotic prophylaxis in onychocryptosis

On the basis of the existing evidence and the recommendations given in the guides of clinical practice, and using an up-to-date system of classification of onychocryptosis in its various degrees of infection depending on the stage of development, we have constructed an algorithm for the use of antibiotic prophylaxis in nail surgery (Fig. 3). We consider the use of antibiotic prophylaxis in certain cases to be fully justified, and protocols of antibiotic management must be established depending on the risk associated to the degree and period of development of the infection, the characteristics of the patient, and the type of surgical procedure performed. We consider that prophylaxis should be not indicated in stages I and II of the pathology. The conservative treatments indicated for stage I of the pathology (extirpation of the nail spicule and of granulation tissue) do not require the use of antibiotics, and the infection can be controlled with antiseptics. In stage III



* Antibiotic prophylactic is not necessary.

**Antibiotic prophylactic: Single dose 30-60 minutes before procedure in risk patients (immunocompromised individuals, cardiac patients, individuals with a previous prosthetic joint infection, or individuals with insulin-dependent diabetes).

***Empiric AB treatment: Broad-spectrum AB treatment (amino-penicillin group) 7-10 days of treatment in addition to preoperative dose.

**** Specific AB treatment: Administration is recommended for at least two weeks before surgery.

•In high-risk cardiac patients with onychocryptosis stage IV and V antibiotic prophylaxis for bacterial endocarditis should be considered

Fig. 3. Algorithm for the use of antibiotic prophylaxis in onychocryptosis surgery.

onychocryptosis, patients at risk (immunocomprised individuals, individuals with a previous prosthetic joint infection, or individuals with insulin-dependent diabetes) who are subjected to incisional techniques and have not received an earlier conservative treatment should be administered antibiotic prophylaxis (a single dose 30 or 60 min beforehand). In patients with an infective onychocryptosis

(stages IV and V), before surgery should be associated antibiotic treatment for 7–10 days at least besides the prophylactic preoperative dose. In infective onychocryptosis (chemical matricectomy is not indicated as it is associated to onycholysis), antibiotic treatment that will depend on the existence of acute or chronic onychocryptosis should be associated to partial ablation of the border or borders.

Table 1 Suggested antibiotics prophylaxis regimens for patients at increased risk of surgical site infection in onychocryptosis surgery.

Patients characteristic	Agent	Adult dose ^a
No PCN allergy	Cephalexin	2 g PO
	OR	
	TMP-SMX-DS	Tablet PO
Patient with PCN allergy	OR	
	Levofloxacin	500 mg PO
	TMP-SMX-DS	1 tablet PO
Patient unable to take PO medication	OR	
	Levofloxacin	500 mg PO
Patient unable to take PO with PCN allergy	Cefazolina/ceftriaxone	1–2 g IM/IV
	Clindamycin	600 mg IM/IV
Infective onychocryptosis (stage IV or V) without osteitis or osteomyelitis signs	Preoperative dose in addition to empiric AB treatment (amino-penicillin group)	
Chronic infected onychocryptosis	Preoperative dose in addition to specific AB treatment for (stage IV or V) with osteomyelitis for pathogen	

IM, intramuscular; IV, intravenous; PCN, penicillin; PO, by mouth. TMP-SMX-DS, trimethoprim-sulfamethoxazole, double strength.

^a In antibiotics profilactic taken orally, administration is recommended 30–60 min before procedure.

Table 2

Suggested antibiotic prophylaxis regimens for nail surgical procedures that involve infective onychocryptosis in patients at high risk for infective endocarditis or hematogenous total joint.

Patients characteristic	Agent	Adult dose ^a
No PCN allergy	Cephalexin OR Dicloxacilina	2 g PO 2 g PO
Patient with PCN allergy	Clindamycin OR Azitromycin/clarithromycin	600 mg PO 500 mg PO
Patient unable to take PO medication	Cefazolina/ceftriaxone	1 g IM/IV
Patient unable to take PO And has PCN allergy	Clindamycin	600 mg IM/IV
Infective onychocryptosis stage IV or V and pathogen known	Antibiotic specific for pathogen ^b	
In a community with increased risk for MRSA	TMP-SMX-DS AND Clindamycin	1 tablet PO 600 mg

IM, intramuscular; IV, intravenous; PCN, penicillin; PO, by mouth; MRSA: methicillin-resistant *S. aureus*.^a 30–60 min is recommended by AHA; 60 min is recommended by the ADA/AAOS.^b Prophylaxis and specific antibiotic treatment must be combined.

It is imperative that the acute phase, with pyogenic abscess formation, be treated to prevent possible inoculation of bone. In this case, a culture and antibiogram should be performed and empirical antibiotic therapy begun, at first covering gram-positives and then, if necessary, specific antibiotic therapy depending on the culture results, until remission of the infection. The treatment should be maintained until the symptoms develop to a lower stage (stages II or III), when the surgical treatment appropriate to the stage reached can be performed. If stage III is reached, a wedge excision (Wino-grad technique) is recommended, together with sanitization of the devitalized tissues. In chronic onychocryptosis (stages IV and V) for 6 months to a year or more, a periosteal reaction may occur following by chronic soft tissue inflammation. When the clinician is challenged with the questionable case of osteomyelitis, radiograph or MRI must be used. The only definitive method of diagnosing osteomyelitis is bone biopsy, so a total or partial nail avulsion with irrigation and drainage and resection of involved bone must be performed. The patient should be free of antibiotics for 48 to 72 h prior to obtaining specimens. The specimen may be cultured for aerobes, anaerobes, fungi, and mycobacteria. In the latter case, administration is recommended of specific treatment two weeks before surgery, maintained at least three weeks after surgery. With the resolution of infection, resection of hypertrophic unguis procedure with or without additional bony debridement must be performed without complications. Finally, consideration should be given to the need for antibiotic prophylaxis for bacterial endocarditis and hematogenous septic arthritis in high-risk cardiac patients (prosthetic cardiac valve, previous infective endocarditis, congenital heart disease, or cardiac transplantation) who are to be surgically treated for onychocryptosis, especially in stage IV and V. The decision to treat higher-risk patients such as immunocompromised individuals, individuals with a previous prosthetic joint infection, or individuals with insulin-dependent diabetes should be dealt with on an individual case-by-case basis in consultation with the patient's cardiologist or orthopedic surgeon. Few studies offer suggestions for antibiotic prophylaxis of surgical site infection in nail surgery. We make recommendations based on organisms most likely to cause infection in the lower extremity surgery, especially leg and foot. Our suggested antibiotic regimen takes this into account, as well as those patients with penicillin allergy. Patients undergoing surgery on infected sites (infective onychocryptosis) should receive antibiotics targeted at cultured pathogens, if known. (Table 1). Current guides recommend prior treatment of infection at the surgery site to reduce the risk of hematogenous bacterial dissemination. Patients with low-risk cardiac indications do not receive antibiotic prophylaxis but would receive therapeutic antibiotics for infected nail surgery. Current evidence does not support the use of preoperative antibiotic prophylaxis in nail surgery except

in special cases. In concordance with the most-current authoritative guidelines, we do recommend prophylactic antibiotics to prevent hematogenous total joint infection or infective endocarditis for onychocryptosis surgery in special cases, nevertheless, in these special cases, interdisciplinary consultation with the patient's cardiologist or orthopedic surgeon seems prudent (Table 2).

7. Conclusions

Current evidence does not support the use of preoperative antibiotic prophylaxis in onychocryptosis surgery except in special patients with infective stage. Antibiotics should be reserved for contaminated or infected onychocryptosis when their application is therapeutic. The adverse effects of prophylactic antibiotics without justification, such as increased cost, adverse drug reactions, development of antibiotic resistance, and medication interactions, should preclude routine use of prophylactic antibiotics. Although the recommendations made in this work are not based on large-scale prospective clinical trials, the authoritative guidelines, together with the existing evidence, have enabled us to establish an algorithm for making clinical decisions enabling a proper management of antibiotics in onychocryptosis surgery. These recommendations provide a point of reference for compliance with the current guidelines, and have been adapted to tackle specific aspects of nail pathology. Managing podiatrist physicians can use these guidelines while individualizing their approach based on all clinical considerations.

References

- [1] Monheit GD. Nail surgery. *Dermatologic Clinics* 1985;3:521–30.
- [2] Rinaldi R, Sabia M, Gross J. The treatment and prevention of infection in phenol alcohol matricectomies. *Journal of the American Podiatric Medical Association* 1982;72:453–7.
- [3] Affleck AG, Birnie AJ, Gee TM, Gee BC. Antibiotic prophylaxis in patients with valvular heart defects undergoing dermatological surgery remains a confusing issue despite apparently clear guidelines. *Clinical and Experimental Dermatology* 2006;31:282–3.
- [4] Heidelbaugh JJ, Lee H. Management of ingrown toenails. *American Family Physicians* 2009;79:303–8.
- [5] Bos AM, van Tilburg MW, van Sorge AA, Klinkenbijn JH. Randomized clinical trial of surgical technique and local antibiotics for ingrowing toenail. *British Journal of Surgery* 2007;94:292–6.
- [6] Reyzelman AM, Trombello KA, Vayser DJ, Armstrong DG, Harkless LB. Are antibiotics necessary in the treatment of locally infected ingrown toenails. *Archives of Family Medicine* 2000;9:930–2.
- [7] Rayan GM, Flournoy DJ. Microbiologic flora of human fingernails. *The Journal of Hand Surgery* 1987;12:605–7.
- [8] Wolf EW, Hodge W, Spielfogel WD. Periungual bacterial flora in the human foot. *The Journal of the Foot and Ankle Surgery* 1991;30:253–63.
- [9] Dixon AJ, Dixon MP, Askew DA, Wilkinson D. Prospective study of wound infections in dermatologic surgery in the absence of prophylactic antibiotics. *Dermatologic Surgery* 2006;32:819–26.

- [10] Heal C, Buettner P, Browning S. Risk factors for wound infection after minor surgery in general practice. *The Medical Journal of Australia* 2006;185:255–8.
- [11] Frasetti L, Weatherhead L. Antibiotic prophylaxis in dermatologic surgery: Is this supported by evidence? *Journal of Cutaneous Medicine and Surgery* 2009;13:119–20.
- [12] Martínez-Nova A, Sánchez-Rodríguez R, Alonso-Peña D. A new onychocryptosis classification and treatment plan. *Journal of the American Podiatric Medical Association* 2007;97:389–93.
- [13] Mozena JD. The Mozena classification system and treatment algorithm for ingrown hallux nails. *Journal of the American Podiatric Medical Association* 2002;92:131–5.
- [14] Kline A. Onychocryptosis: a simple classification system. *The Foot and Ankle Journal* 2008;1:6–13.
- [15] Cox HA, Jones RO. Direct extension osteomyelitis secondary to chronic onychocryptosis. Three case reports. *Journal of the American Podiatric Medical Association* 1995;85:321–4.
- [16] Weaver TD, Ton MV, Pham TV. Ingrowing toenails: management practices and research outcomes. *The Internal Journal of Lower Extremity Wounds* 2004;3:22–34.
- [17] Laco JE. Operative care of nail disorders. In: Levy LA, Hetherington VJ, editors. *Principles and practice of Podiatric Medicine*. 2nd ed. New York: Churchill Livingstone; 1990. p. 1–19.
- [18] Rounding C, Hulm S. Surgical treatments for ingrowing toenails. *Cochrane Database System Review* 2000;2. CD 001541.
- [19] Hirschmann JV. Antimicrobial prophylaxis in dermatology. *Seminars in Cutaneous Medicine and Surgery* 2000;19:2–9.
- [20] Fernandez-Ospina N, García-Carmona FJ. *Patología y Cirugía Ungueal*, 1st ed. Madrid; 2008. p. 18–32.
- [21] Zack L, Remlinger K, Thompson K, Massa MC. The incidence of bacteremia after skin surgery. *The Journal of Infectious Diseases* 1989;159:148–50.
- [22] Sabetta JB, Zitelli JA. The incidence of bacteremia during skin surgery. *Archives of Dermatology* 1987;123:213–5.
- [23] Carmichael AJ, Flanagan PG, Holt PJ, Duerden BI. The occurrence of bacteraemia with skin surgery. *British Journal of Dermatology* 1996;134:120–2.
- [24] Bobrow BJ, Pollack CV, Gamble S, Seligson RA. Incision and drainage of cutaneous abscesses is not associated with bacteraemia in afebrile adults. *Annals of Emergency Medicine* 1997;29:404–8.
- [25] Trepal MJ, Brunetti V, Hodge WR. Intraoperative bacteremia during foot surgery. *Journal of Foot Surgery* 1988;27:47–51.
- [26] Messingham MJ, Arpey CJ. Update on the use of antibiotics in cutaneous surgery. *Dermatologic Surgery* 2005;31:1068–78.
- [27] Robinson C. Cutaneous surgery reconsidering electrosurgery. *Journal of the American Podiatric Medical Association* 2009;99:353–8.
- [28] Abbott WW, Geho EH. Partial matricectomy via negative galvanic current. *Journal of the American Podiatric Medical Association* 1980;70:239–43.
- [29] Farley-Sakevich T, Grady JF, Zager E, Axe TM. Onychoplasty with carbon dioxide laser matrixectomy for treatment of ingrown toenails. *Journal of the American Podiatric Medical Association* 2005;95:175–9.
- [30] Wright TI, Baddour LM, Berbari EF, Roenigk RK, Phillips PK, Jacobs MA, et al. Antibiotic prophylaxis in dermatologic surgery: advisory statement 2008. *Journal of the American Academy of Dermatology* 2008;59:464–73.
- [31] Wilson W, Taubert KA, Gewitz M, Lockhart PB, Baddour LM, Levison M., et al. Prevention of infective endocarditis. Guidelines from the American Heart Association. A guideline from the American Heart Association Rheumatic Fever, Endocarditis, and Kawasaki Disease Committee, Council on Cardiovascular Disease in the Young, and the Council on Clinical Cardiology, Council on Cardiovascular Surgery and Anesthesia, and the Quality of Care and Outcomes Research Interdisciplinary Working Group. *Journal of the American Dental Association* 2007;138:739–45.